
7. The Large Intestine Channel System (Hand Yang Ming) 手陽明大腸經

7.1 The Primary Large Intestine Channel

Pathway: The hand yang ming large intestine channel begins at the radial side of the tip of the index finger and proceeds upward between the first and second metacarpal bones of the hand and between the tendons of the extensor pollicis longus and brevis muscles at the wrist. It continues along the radial margin of the forearm to the radial margin of the lateral aspect of the elbow, then up the lateral aspect of the upper arm and over the shoulder joint. After intersecting the hand tai yang small intestine channel at SI-12, it rises to just below the spinous process of the seventh cervical vertebra, and intersects with the governing vessel at GV-14, where all six yang regular channels meet. It then travels straight into the supraclavicular fossa to ST-12, from where it connects through to the lung, passes through the diaphragm, and homes to the large intestine.

A branch separates from the main channel at ST-12 in the supraclavicular fossa, passes up the neck, and traverses the cheek before entering the lower gum. From here it skirts around the lips, passes the foot yang ming channel at ST-4, and then meets the same channel coming from the other side of the body at the **philtrum**. It then continues around the nostril of the opposite side to terminate at the side of the nose. In other words, the right and left channels cross over at the **philtrum** and run for the last short stretch on the opposite side of the body from which they originated.

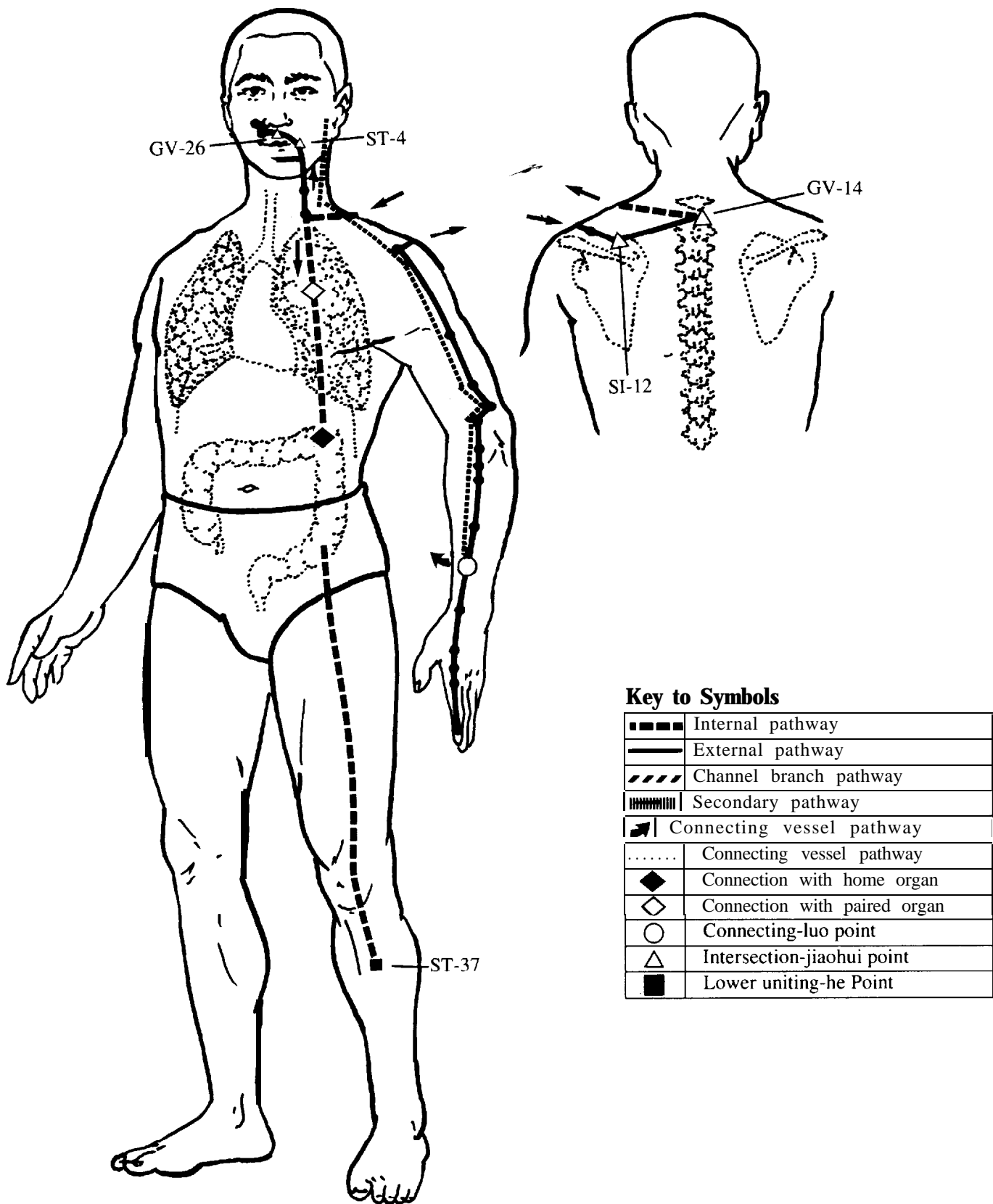
The *Spiritual Axis* describes yet another branch that separates from the main channel at ST-12, descends past ST-13 and penetrates the lung, passes through the diaphragm, homes to the large intestine, and descends to the lower limb to emerge at ST-37, which is the lower uniting-point of the large intestine.

Main pathologic signs associated with the external course of the channel: fever, parched, dry mouth and thirst, sore throat, nosebleed, toothache, pain and reddening of the eyes, swelling of the neck, palpable red swelling and inhibited bending and stretching of the fingers. There may also be pain, sensation of cold, or painful and palpably hot, red swelling in the region of the shoulder and upper arm.

Main pathologic signs associated with the internal organ: lower abdominal pain, migratory abdominal pain, borborygmi, thin stool, and excretion of thick, slimy yellow matter. There may also be rapid breathing and dyspnea.

Exuberance of qi: Distention swelling and heat along the course of the channel.

Insufficiency of qi: Cold and shivering with an inability to regain warmth.



7.2 The Connecting Vessel of the Large Intestine Channel

Pathway: This vessel separates from the primary channel 3 " proximal to the wrist at LI-6 and branches to the lung channel. Another branch separates from the primary channel at the same point and rises up the arm, passes through the shoulder region and proceeds to the corner of the jaw, from where it separates into two branches. One branch spreads over the teeth and another enters the ear to unite with the channels of the gallbladder, triple burner, small intestine, and stomach.

Main pathologic signs:

Symptoms of repletion: Tooth decay; deafness.

Symptoms of vacuity: Tooth sensitivity to cold; bi.

7.3 The Large Intestine Channel Divergence

Pathway: After leaving the primary channel at the shoulder near LI-15 and crossing over to the 7th cervical vertebrae this divergence then enters the body cavity and proceeds downward to the large intestine. It also homes to the lung from where it rises along the throat and surfaces again to join its primary channel, the hand yang ming (LI).

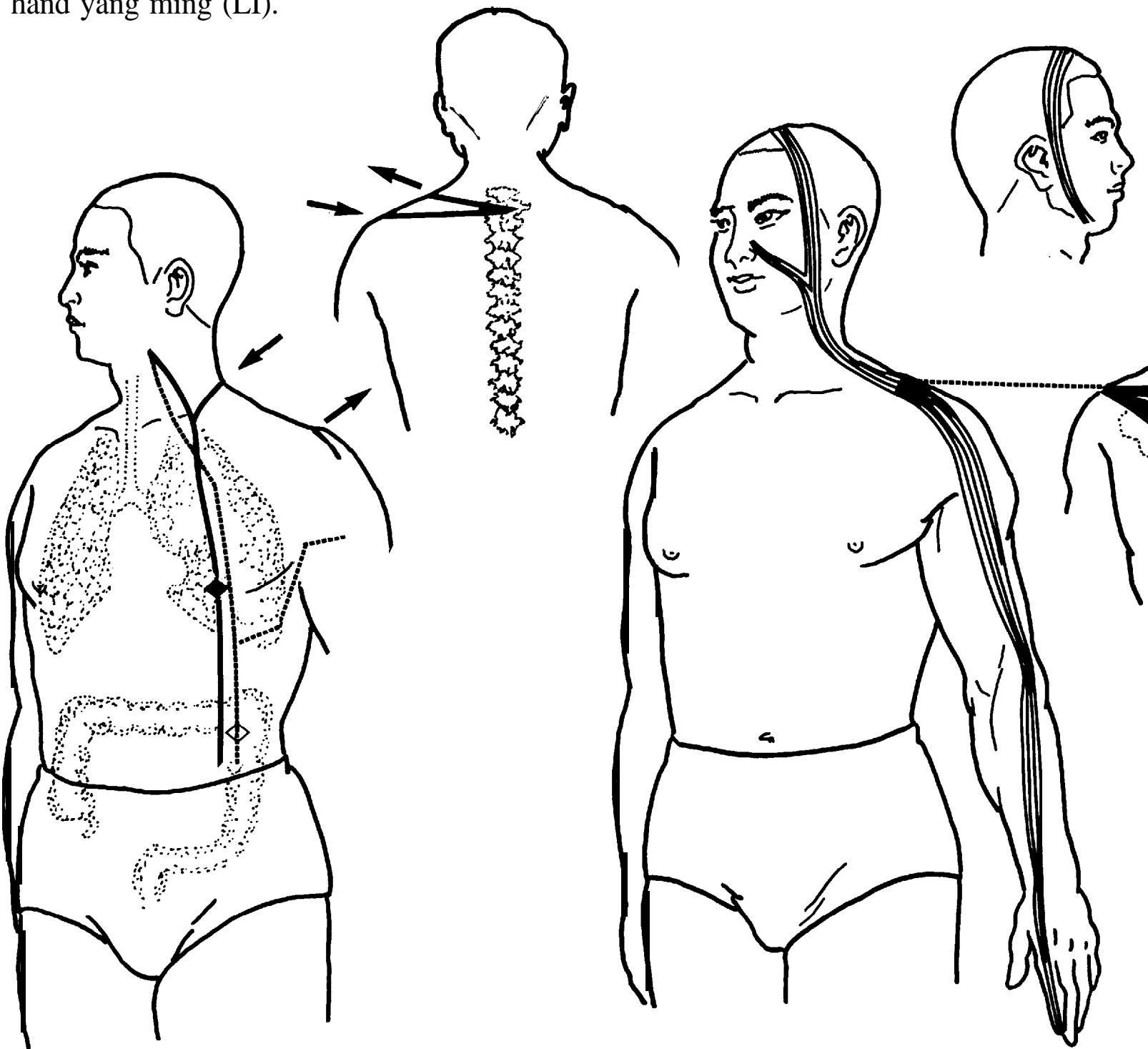


Figure 7.3 Channel divergences of the large intestine and lung.

Figure 7.4 The large intestine channel sinews.

7.4 The Large Intestine Channel Sinews

Pathway: The sinew begins at the tip of the index finger and binds at the dorsal aspect of the wrist. It then proceeds up the forearm and binds at the lateral aspect of the elbow, and continues upward along the lateral aspect of the upper arm and binds at the shoulder.

One branch breaks from the shoulder, wraps the scapula and clasps to the spine. Another branch separates from the shoulder and proceeds upward along the neck. This branch splits at the jaw and one fork binds at the side of the nose while the other follows anterior to the small intestine channel sinew up over the head to bind at the submandibular region on the opposite side of the head.

Main pathologic signs: Spasms, stiffness, pain or strain along the course of the channel sinew; inability to raise the arm; inability to turn the neck to the left or right.

Location: On the radial side of the index finger, about 0.1" proximal to the corner of the nail.

Classical Location: On the inside of the index finger, the width of Chinese leek leaf from the corner of the nail.

(The Great Compendium)

Local Anatomy: The arterial and venous network formed by the dorsal and digital arteries and veins. The palmar digital proprial nerve derived from the median nerve.

Functions: Resolves the exterior and abates heat; clears the lung and disinhibits the throat; courses and discharges yang ming pathogenic heat; opens the portals and revives the spirit.

Indications: Toothache; sore, swollen throat; swelling of the submandibular region; numbness of the fingers; heat diseases; clouding inversion.

Supplementary Indications: Heat disease with sweating; blindness; deafness and tinnitus; throat bi preventing speech; shoulder and back pain reaching into the clavicle; cold and heat malaria; thoracic qi fullness.

Illustrative Point Combinations & Applications: A principal use of LI-1 is in treating sudden wind strike and fulminant clouding with phlegm congestion. *(The Golden Mirror of Medicine)*

Stimulation: 0.1" upward oblique insertion; bleed as for LU-11.

Moxa: 1-3 cones; pole 5 min.

Point Categories & Associations: Well-jing (metal) point.

Location: On the radial side of the index finger, distal to the metacarpophalangeal joint, at the border of the red and white skin. The point is located with the finger slightly flexed.

Classical Location: On the inner side of the index finger, in the depression at the base joint. *(The Great Compendium)*

Local Anatomy: The dorsal digital and palmar digital proprial arteries and veins derived from the radial artery and vein. The dorsal digital nerve of the radial nerve and the palmar digital proprial nerve of the median nerve.

LI-1

商陽

shāng yáng

“Shang Yang”

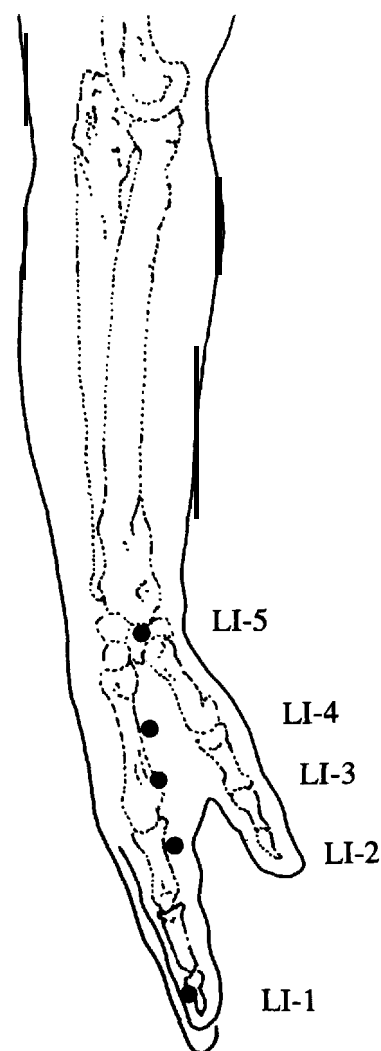


Figure 7.5

LI-2

二間

èr jiān

“Second Space”

Functions: Dissipates pathogenic heat; disinhibits the throat.

Indications: Clouded vision; nosebleed; toothache; sore, swollen throat; heat diseases.

Supplementary Indications: Severe clouding of vision; throat bi; submandibular swelling; shoulder and back pain; wryness of mouth and eyes; headache.

Illustrative Point Combinations & Applications: Dong Shi Jing Chang uses this point contralaterally to treat low back pain.

Note: Dong Shi Jing Chang was a well known acupuncturist (1916-1975) who used points in a non-traditional fashion. His treatments were known to be quite effective and for this reason some are included in this book.

Stimulation: 0.2-0.3" perpendicular insertion.

Moxa: 3 cones; pole 5 min.

Point Categories & Associations: Spring-ying (water) point.

LI-3

三間

sān jiān

“Third Space”

Location: On the radial side of the index finger proximal to the head of the 2nd metacarpal bone. Easily located when a loose fold of skin is formed.

Classical Location: In the depression behind the base joint of the index finger, on the inner side. (*The Great Compendium*)

Local Anatomy: The dorsal venous network of the hand and the branch of the 1st dorsal metacarpal artery. The superficial ramus of the radial nerve.

Functions: Discharges pathogenic heat; disinhibits the throat; regulates bowel qi.

Indications: Eye pain; toothache; sore, swollen throat; redness and swelling of the fingers and backs of the hands.

Supplementary Indications: Acute eye pain; aching among the lower teeth; throat bi; blockage of the pharynx; fever and chill; abdominal fullness and rumbling intestines; shoulder pain; dryness of the mouth and lips; body fever; dyspnea; fecal stoppage.

Illustrative Point Combinations & Applications: There is the wonder of LI-3, and BL-23, which are good for treating wind and pain in the shoulder and back. (*Ode of Xi Hong*)

Stimulation: 0.5-1 .0 " perpendicular insertion.

Moxa: 3 cones; pole 5-10 min.

Point Categories & Associations: Stream-shu (wood) point.

Location: In the center of the flesh between the 1st and 2nd metacarpal bones, slightly closer to the 2nd metacarpal bone. If the transverse crease of the interphalangeal joint of the thumb of one hand is lined up with the margin of the web between the thumb and the index finger of the other hand, the point is where the tip of the thumb touches.

Classical Location: In the depression where the index finger and thumb bones part. (*The Great Compendium*)

Local Anatomy: The venous network of the dorsum of the hand; proximally, exactly on the radial artery piercing from the dorsum to the palm of the hand. The superficial **ramus** of the radial nerve; deeper, the **palmar** digital proprial nerve derived from the median nerve.

Functions: Frees the channels and quickens the connecting vessels; courses wind and resolves the exterior; clears and discharges lung heat; frees gastrointestinal downbearing; relieves pain and quiets the spirit.

Indications: Headache; painful swelling and reddening of the eyes; nosebleed; swelling of the face; sore, swollen throat; hypertonicity of the fingers; pain in the arm; wryness of the eyes and mouth; sweating or absence of it in heat diseases; menstrual block; prolonged labor; dysentery.

Supplementary Indications: Wind strike trismus; malaria with fever and chills; mania; loss of voice; wind papules; cardiac pain; unilateral or ambilateral headache; great thirst, fever and aversion to cold in cold damage; headache and rigid spine; child throat moth.

Stimulation: 0.5-0.8" perpendicular insertion.

Moxa: 3 cones; pole 5-15 min.

Needle Sensation: Distention and numbness, spreading down to the fingers or up to the elbow, sometimes radiating into the shoulder or even the face.

Contraindications: This point is contraindicated for pregnant women.

LI-4

合谷

hé gǔ

"Union Valley"

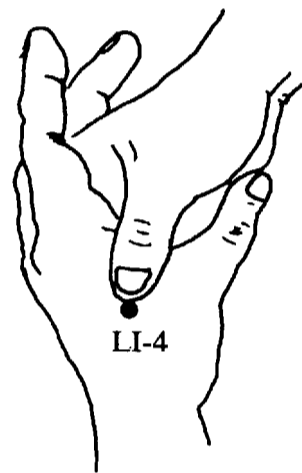


Figure 7.6